



ELSEVIER

NeuroImage

www.elsevier.com/locate/ynimg
NeuroImage xx (2006) xxx–xxx

Imaging correlates of motor recovery from cerebral infarction and their physiological significance in well-recovered patients

Dinesh G. Nair, Siobhan Hutchinson, Felipe Fregni, Michael Alexander, Alvaro Pascual-Leone, and Gottfried Schlaug*

Department of Neurology, Palmer 127, Beth Israel Deaconess Medical Center/Harvard Medical School, 330, Brookline Avenue, Boston, MA 02215, USA

Received 21 April 2006; revised 9 September 2006; accepted 14 September 2006

We studied motor representation in well-recovered stroke patients. Eighteen right-handed stroke patients and eleven age-matched control subjects underwent functional Magnetic Resonance Imaging (fMRI) while performing unimanual index finger (abduction–adduction) and wrist movements (flexion–extension) using their recovered and non-affected hand. A subset of these patients underwent Transcranial Magnetic Stimulation (TMS) to elicit motor evoked potentials (MEP) in the first dorsal interosseous muscle of both hands. Imaging results suggest that good recovery utilizes both ipsi- and contralesional resources, although results differ for wrist and index finger movements. Wrist movements of the recovered arm resulted in significantly greater activation of the contralateral (lesional) and ipsilateral (contralesional) primary sensorimotor cortex (SM1), while comparing patients to control subjects performing the same task. In contrast, recovered index finger movements recruited a larger motor network, including the contralateral SM1, Supplementary Motor Area (SMA) and cerebellum when patients were compared to control subjects. TMS of the lesional hemisphere but not of the contralesional hemisphere induced MEPs in the recovered hand. TMS parameters also revealed greater transcallosal inhibition, from the contralesional to the lesional hemisphere than in the reverse direction. Disinhibition of the contralesional hemisphere observed in a subgroup of our patients suggests persistent alterations in intracortical and transcallosal (interhemispheric) interactions, despite complete functional recovery.

© 2006 Elsevier Inc. All rights reserved.

Introduction

Rehabilitative measures aimed at improving motor recovery following stroke are based on the tenet that neural structures (especially the motor cortex) have the potential for rapid and large-scale functional changes such as those seen in motor skill learning (Seitz et al., 1990; Classen et al., 1998; Nudo et al., 2001; Nudo, 2003). However, whether these changes really represent or directly

contribute to functional improvement is not fully known. Studying neural representations of movements will help us identify the brain areas which when spared, contribute to a favorable prognosis and those which when affected, result in an incomplete recovery. For instance, consistent activity in the primary motor cortex on functional Magnetic Resonance Imaging (fMRI) and a working pyramidal tract in the lesional hemisphere as demonstrated by Transcranial Magnetic Stimulation (TMS) in well-recovered patients or the absence of such in patients with residual disability would imply the need for a working pyramidal tract for complete recovery. Hence, studying the changes in motor representation in well-recovered patients is crucial to the understanding of the brain mechanisms associated with motor recovery following stroke.

Previous studies, both cross-sectional and longitudinal, have addressed the issue of motor recovery from stroke. Important results from these studies can be summarized as (a) Focusing of activation—the initial widespread activation of the primary motor (M1) and other areas such as the Supplementary Motor Area (SMA), Cerebellum, Premotor, Parietal and Insula, becomes less widespread and focused (Chollet et al., 1991; Weiller et al., 1992; Nelles et al., 1999; Ward et al., 2003); (b) Change in laterality—an initial increase in activity in the contralesional primary sensorimotor cortex changes to more ipsilesional activity (Marshall et al., 2000; Calautti et al., 2001; Johansen-Berg et al., 2002a); and (c) Activation in the peri-infarct region (Cramer et al., 1997; Luft et al., 2004a). The temporal evolution of neural activation and reorganization revealed by these studies suggest that well-recovered patients, despite being able to perform motor tasks and being functionally independent, may have a different representation of hand movements after recovery than age-matched control subjects. Since neural plasticity plays a major role in motor recovery from stroke, it is also plausible that one can observe functional imaging markers of neural plasticity such as a change in location of peak activation in well-recovered patients compared to control subjects performing the same task.

Our study aimed at understanding the neural correlates of motor recovery by examining (1) differences in motor representation of early and later recovering movements (Brunnstrom, 1966; Fugl-Meyer et al., 1975; Duncan et al., 2000) in well-recovered stroke

* Corresponding author. Fax: +1 617 632 8920.

E-mail address: gschlaug@bidmc.harvard.edu (G. Schlaug).

Available online on ScienceDirect (www.sciencedirect.com).

patients comparing them to a matched group of normal controls, (2) differences in physiological parameters of the pyramidal system in the recovered and unaffected hemisphere as well as inter-hemispheric interactions, and (3) the structure–function relationship of brain regions involved in motor recovery using fMRI and TMS. We chose patients who had moderate to severe motor impairment at admission and who slowly progressed to being well-recovered over a few months.

It is known that motor recovery after stroke follows a clinically recognized temporal sequence, from the initiation of volitional movement with synergies to the development of isolated movement unaffected by synergy (Brunnstrom, 1966; Fugl-Meyer et al., 1975). Although, a longitudinal design examining neural representations of these movements might be ideal, since all our subjects were well-recovered and some subjects were reluctant to undergo multiple test sessions, we decided to use two movements instead—one that represents an earlier part of the recovery process, i.e., wrist extension and flexion, and the other, a later time point in the recovery process, i.e., isolated index finger movements (Brunnstrom, 1966; Fugl-Meyer et al., 1975; Duncan et al., 2000). A comparison of the representation of these movements in this group of functionally well-recovered stroke patients and age-matched control subjects would reveal differences in movement representation following recovery from stroke.

Additionally, in order to examine whether the uncrossed pyramidal tract is directly involved in recovery, we applied a maximal intensity TMS pulse to the contralesional M1 of patients and recorded motor evoked potentials from the ipsilateral (recovered) hand. Finally, we also studied transcallosal (interhemispheric) inhibition between the lesional and contralesional hemispheres and used paired pulse stimulation to study intracortical inhibition (ICI) and facilitation (ICF). Since previous TMS studies reported altered transcallosal inhibition following a stroke (Shimizu et al., 2002, Murase et al., 2004, Duque et al., 2005), we were interested in understanding the nature of this transcallosal

interaction following complete functional recovery. If indeed disinhibition (loss of inhibition from the lesional to the contralesional hemisphere) persisted following the infarction, we would expect to see larger transcallosal inhibition from the contralesional to the lesional hemisphere than from the lesional to the contralesional hemisphere. Similarly, intracortical facilitation will be greater in the contralesional compared to the lesional hemisphere, while the reverse will be true for intracortical inhibition. In this study, we also relate fMRI activation patterns in the lesional and contralesional hemispheres during motor tasks to TMS parameters of inhibition and facilitation, in order to better understand the functional relevance of neural activation observed in this group of well-recovered patients.

Materials and methods

Subjects

Eighteen right-handed patients, aged 24–80 years, who suffered their first ever infarct, participated in the study. Eleven patients had lesions in the right hemisphere (6 patients had predominantly cortical lesions including the immediate underlying subcortical region+5 patients had lesions of the deep white matter/striato-capsular region) and seven in the left (6 patients had predominantly cortical lesions including the immediate underlying subcortical region+1 patient had a striato-capsular/thalamo-capsular lesion). Patient details (e.g., age, gender, time elapsed after the stroke, initial NIH stroke scale; Orpington Prognostic Scale within 48 h of the stroke, the NIH stroke scale and their MRC muscle strength at fMRI/TMS) are given in Table 1. All patients signed an informed consent form approved by the Institutional Review Board. Patients with a previous history of stroke, bilateral infarcts, hemorrhage, chronic pain and other neurological diseases were excluded from participating in the study. None of the patients were on anti-depressant medication. Patients' initial assessment at the time of

Table 1
Demographic details of stroke patients

Patient #	Affected hemisphere	Sex	Age	Time between stroke and fMRI/TMS (months)	NIHSS at admission	OPS within 48 h of admission	NIHSS at fMRI/TMS	MRC (WE, FDI) at fMRI/TMS
1	R	M	60	25	9	4.0	1	5–, 5–
2	R	M	61	5	17	4.8	1	5, 5–
3	R	M	55	5	4	3.2	0	5, 5
4	R	M	62	10	8	3.6	0	5, 5
5	R	M	55	2.5	4	2.4	0	5, 5
6	R	M	54	4.5	5	2.8	1	5–, 5–
7	R	F	24	2.5	9	3.2	0	5, 5
8	R	F	24	7	12	5.2	1	5–, 5–
9	R	M	52	12	8	3.6	0	5, 5–
10	R	M	75	2	4	2.4	1	5–, 5–
11	R	F	54	14	9	4.0	1	5–, 5–
12	L	M	69	24	7	3.2	0	5, 5
13	L	M	80	10	4	2.8	0	5, 5–
14	L	M	71	6	11	4.0	1	5–, 5–
15	L	M	79	2.5	13	5.2	1	5–, 5–
16	L	M	30	96	9	3.2	1	5, 5
17	L	M	68	4	16	5.2	1	5–, 5–
18	L	M	77	2	7	2.4	0	5, 5

R=Right; L=Left; NIHSS—National Institutes of Health Stroke Scale; OPS—Orpington Prognostic Scale; The MRC muscle strength grade is reported for wrist extension (WE) and the first dorsal interosseus muscle (FDI). By convention, the maximal reported strength is 5 out of 5. All of our well-recovered patients achieved at least 5– out of 5. The two numbers in the last column refer to the strength of the wrist extension (first number) and the first dorsal interosseus muscle (second number).

their stroke comprised of a detailed neurological exam including an assessment of flexor/extensor strength in the upper and lower extremity using the MRC strength grade classification, an admission NIH Stroke Scale (NIHSS) (mean (\pm SE)=8.67 \pm 0.93), and the Orpington Prognostic Scale (OPS) (Kalra and Crome, 1993; Duncan et al., 2000). All of our patients had MRC grades of 3/5 or less in their wrist and finger extensors and interossei, and showed additional signs suggesting pyramidal tract impairment (e.g., severe slowing of fine finger movements, abnormal reflexes) at admission. Further evidence of their moderate to severe impairment was that none of our patients showed rapid reversal of their initial deficits and all of them required inpatient rehabilitation. All patients showed good recovery within 2–6 months after the initial stroke. However, we enrolled patients in this cross-sectional study after they responded to study flyers and following a detailed neurological examination and careful review of their medical records at the time of enrollment. Consequently, some patients were more than 1 year post-stroke when they were enrolled in this study. None of our patients had any restrictions in their activities of daily living at enrollment. They all achieved Barthel Indices of >95, NIHSS of one or less and an MRC grade of 5– or 5. Eleven age-matched control subjects (mean age 60 years) with no neurological diseases were also studied using the same protocol. All control subjects had normal T1- and T2-weighted scans.

Lesion mapping

Lesion mapping was done according to previous descriptions (Rorden and Karnath, 2004; Karnath et al., 2004). We used the ROI toolbox of the MRICro software (Rorden and Brett, 2000) to map the lesion location. First, the chronic lesion seen in the FLAIR images (acquired along with EPI scans) was compared with the acute imaging (usually diffusion weighted images obtained at admission) to confirm the exact location of the lesion. The FLAIR images obtained for each patient had a resolution of 0.5 \times 0.5 \times 5 mm and were resampled into 2 \times 2 \times 2 mm after normalization. Using, MRICro we then outlined the location and extent of the lesion on the normalized FLAIR images. The lesion mask of each patient was then overlaid on their respective T1-weighted images. A set of representative T1-weighted axial slices showing the extent and location of the lesion is shown in Table 2. In addition, the lesion maps from all patients ($N=18$; left hemisphere lesions were flipped along the mid-sagittal axis) were overlaid on a standardized T1-weighted template to create a summary image of all lesions, in order to delineate the degree of overlap and extent of lesions.

Table 2 also includes information on whether the lesion involved the primary motor cortex (M1), dorsal premotor cortex (PMd), and supplementary motor area (SMA proper). Since there are only a few gross anatomical landmarks that correspond to cytoarchitecturally defined Brodmann areas, we relied on criteria that have been published in the literature (Eickhoff et al., 2005; Zilles et al., 1995) to determine the approximate locations of M1, PMd, and SMA. In short, M1 was regarded to occupy the posterior bank of the precentral gyrus from the deepest point of the sulcus to the lateral crest of the gyrus; we defined the core region of the PMd as the anterior and posterior banks of the precentral sulcus above the inferior frontal sulcus; the SMA proper was defined as the region of the posterior mesial frontal cortex that is in between two vertical lines that pass through the anterior and posterior commissure and above the cingulate sulcus (see also Eickhoff et al., 2005; Zilles et al., 1995).

Motor tasks

Patients and control subjects performed two motor tasks while in the scanner: (1) full wrist extension and flexion and (2) full index finger abduction and adduction. Subjects performed these movements unimanually, first using the non-affected hand and then the recovered hand. Movements were paced by a metronome at 1 Hz played to the subject through MRI compatible headphones. Subjects were asked to have their eyes closed, listen to the metronome and make a full excursion (flexion+extension or abduction+adduction) at this rate (1 Hz). One of the investigators stood beside the subject in the scanner to observe whether the tasks were performed as instructed and at the required pace.

Image acquisition

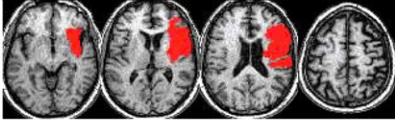
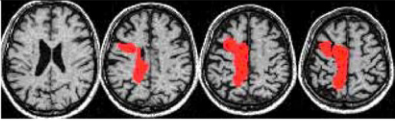
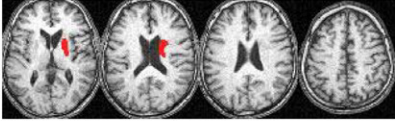
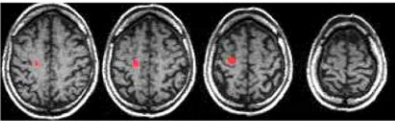
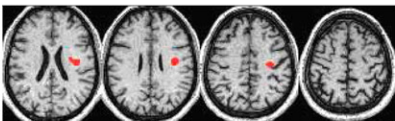
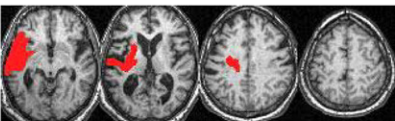
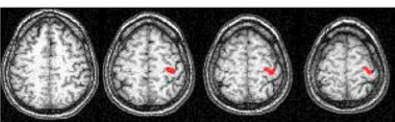
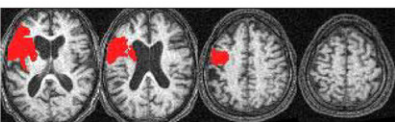
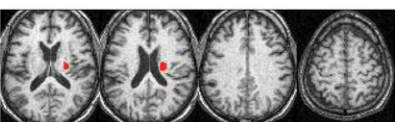
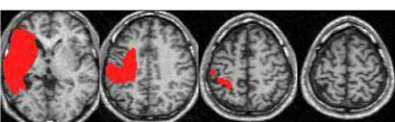
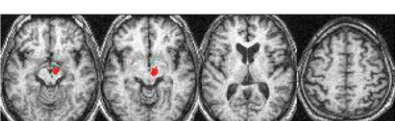
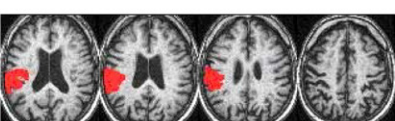
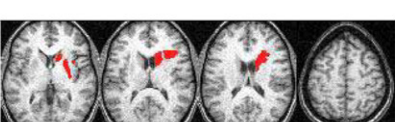
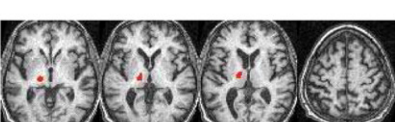
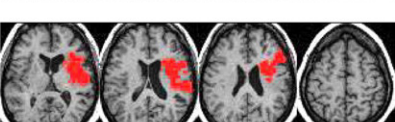
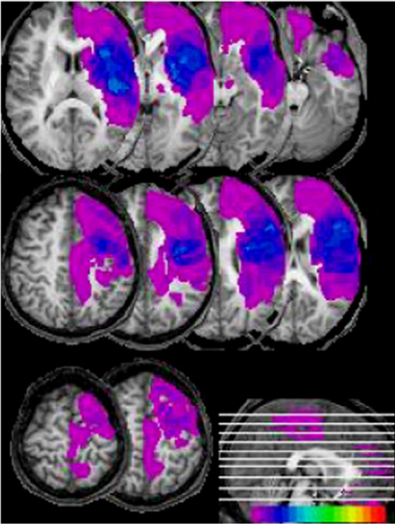
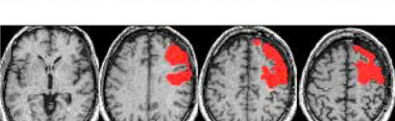

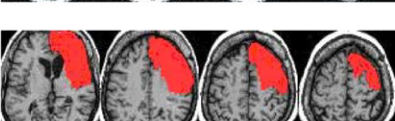
Subjects were scanned using a 1.5 T GE scanner using a standard radiofrequency coil. Head motion was minimized by using foam padding and forehead restraining straps. A gradient echo T2* weighted echo planar (EPI) sequence was used to acquire 32 contiguous axial slices, parallel to the anterior–posterior commissure plane and covering the entire brain. A block design of 35 s ON (task) and 35 s OFF (rest) epochs was used for functional imaging and image acquisition started with the rest phase. Movement (ON) blocks were interspersed with 35 s rest (OFF) blocks. The metronome was on during the “Movement (ON)” as well as during the “Rest (OFF)” blocks. Subjects were asked to relax, not to make any movements and not to think about any movement during the rest blocks. There were five acquisitions per epoch, with a clustered volume acquisition time of 2.6 s and a delay of 4.4 s between acquisitions, thus making the effective TR=7 s. A set of axial FLAIR images was also acquired to rule out the possibility of any new infarct.

fMRI data analysis

Off-line data preprocessing including image realignment, normalization and spatial smoothing using a Gaussian kernel with FWHM 8 mm was done using SPM99 (Friston et al., 1995a). For patients with extensive lesions, we used MRICro (Rorden and Brett, 2000) to mask the lesion in order to perform an accurate spatial normalization (Brett et al., 2001). Voxels with task-related activity were identified by using the General Linear Model (GLM) approach for time series data suggested by Friston et al. (1995b). A boxcar reference vector was convolved with the canonical hemodynamic response function to model the expected blood oxygenation level dependent (BOLD) response. We flipped the functional and anatomical data of patients with left-sided lesions about the mid-sagittal plane, to perform a group analysis with all eighteen patients. This essentially allowed us to consider all patients as having had a right-hemisphere lesion.

To compare differences in brain activation during the motor tasks between stroke patients and control subjects, a second level (random effects) analysis with a uniform probability threshold was done ($p<0.001$, uncorrected). To correct for alpha inflation, a significant cluster of activation was defined as comprising of at least 20 contiguous voxels. We are aware that, in order to show population effects using a random effects analysis, it is usually suggested to have a group of about 12 subjects. Although our patient group has an $N=18$, our control subject group is just short of this number ($N=11$). Moreover, to decrease the chance of

Table 2
Location and extent of lesions in all stroke patients

Patient #	Lesion location and extent in patients with right hemisphere infarcts	Selected motor areas involved	Patient #	Lesion location and extent in patients with left hemisphere infarcts	Selected motor areas involved
1		M1, PMd	12		PMd, SMA
2		–	13		M1, PMd
3		M1	14		PMd
4		M1	15		M1, PMd
5		–	16		M1, PMd
6		–	17		M1
7		–	18		–
8		M1, PMd			
9		M1, PMd			
10		–			
11		M1, PMd			

reporting false positive results, we combined cluster thresholding and probability thresholding. In order to determine whether the neural representation of movements following recovery in these right-handed individuals was determined by the hemisphere affected by stroke (dominant or non-dominant hemisphere), we computed the mean brain activation during each task subdividing patients into two groups—right hemisphere (RH) and left hemisphere (LH) stroke patients. The mean activation in these two patient groups was then separately compared with that of control subjects for the same task. Active voxels in the primary sensorimotor cortex (SM1) were then identified using the Wakeforest University atlas (www.fmri.wfubmc.edu/downloads/WFU_PickAtlas_User_Manual.pdf, WFU PickAtlas 2.0, integrated into SPM99) and the location of the voxel with peak activation (x , y and z coordinates in Talairach space) within the SM1 cluster noted ($p < 0.001$). To quantify the intensity of the functional response following recovery, the amplitude at the locations of the peak activation was also measured—this corresponds to the coefficient of the task effect in the GLM, the so called size effect in SPM, given by the beta parameter. A two-sample t -test was used to determine whether the coordinates (x , y or z) of the maximally activated voxel were significantly different in the two patient groups (right-hemisphere lesion and left-hemisphere lesion) compared to the control subjects.

TMS experiment

Subjects were seated in a reclining chair during TMS and recording of motor evoked potentials (MEP). A 70-mm figure-eight coil and a Magstim 200 and Bistim module (Magstim, Dyfed, UK) were used for single- and paired-pulse TMS. MEPs were recorded from the first dorsal interosseous (FDI) muscle of both hands. Motor threshold (MT) was determined as outlined by Rossini et al. (1994). Once the optimal scalp positions and MT in both hemispheres were determined, patients underwent a series of tests. These included: (1) recruitment (input–output) curve, (2) intracortical inhibition (ICI) and facilitation (ICF)—by paired pulse stimulation using a single coil (Kujirai et al., 1993) (the details of the methodology for recruitment curves and ICI and ICF are given in Theoret et al., 2005), (3) transcallosal inhibition—a conditioning pulse delivered to the motor cortex of one hemisphere, was followed 10 ms later by a test stimulus to the opposite hemisphere. The strength of the pulse was set to 120% of the resting MT of the hemisphere to which the pulse was applied. The inter-pulse interval of 10 ms was chosen because it has been shown in previous studies to result in transcallosal inhibition (Meyer et al., 1995; Kobayashi and Pascual-Leone, 2003) and would allow us to observe the nature of transcallosal conduction following recovery from stroke. We measured transcallosal inhibition, both from the lesional to contralesional, and the contralesional to the lesional hemisphere, recording each pair 10 times. (4) In all subjects, we applied TMS on the contralesional hemisphere using a stimulus of maximal intensity (up to 100% of the stimulator output) and recorded 10 MEPs from the FDI in the recovered and non-

affected hands, in order to determine whether this elicited MEPs in the recovered hand.

TMS data analysis

We were able to gather TMS data from nine patients (5 right-hemisphere lesion patients and 4 left-hemisphere lesion patients). Other patients in the group were either not eligible for TMS or did not agree to participate in the TMS part of the study. First, the resting motor thresholds in the lesional and contralesional hemispheres were compared using a paired t -test. Mean area under the MEP curves at different stimulus strengths was then calculated and used to plot the input–output curve. Input–output curves were plotted for both the lesional and contralesional hemispheres to look for differences in recruitment. In order to study intracortical inhibition (ICI) and intracortical facilitation (ICF), the mean peak-to-peak amplitude of the control and test MEP at each inter-pulse interval was calculated. The mean peak-to-peak amplitudes of MEPs at inter-pulse intervals 1, 2 and 3 ms in each subject were averaged to obtain a representative value for ICI, and that at 9 and 12 ms intervals, for ICF. These values were calculated for both the lesional as well as the contralesional hemispheres for all subjects.

Mean area under the curve of MEPs from both FDI was calculated to evaluate transcallosal inhibition. The baseline (control) was the mean MEP area calculated from trials with the test pulse alone and inhibition was expressed as percentage of the baseline for each subject. The percentage of inhibition ($1 - (\text{test}/\text{control})$) from the contralesional to the lesional hemisphere (CtoL) and vice-versa (LtoC), were then expressed as a ratio (CtoL/LtoC). This ratio helped us to avoid the differences due to varying absolute values of inhibition across subjects, and provided us with a within-subject normalized, quantitative parameter to assess the nature of transcallosal inhibition. Finally, MEPs from the recovered and non-affected FDI were recorded using the maximum (100%) strength stimulus to test whether stimulation of the contralesional hemisphere results in an ipsilateral response (MEPs in the recovered hand).

Correlating TMS findings with fMRI

For all subjects on whom we have complete TMS data sets (only eight patients had complete ICI and ICF data sets), we decided to explore whether there is evidence for disinhibition of the contralesional hemisphere in their fMRI and TMS data.

Regions of interest (ROI) representing the primary motor cortex were drawn manually using MRICro (Rorden and Brett, 2000) over the posterior part of the pre-central gyrus on normalized T1 axial slices with Z coordinates 32–62 in the Talairach coordinate system (Mottaghy et al., 2003). This ROI was then overlaid onto the beta images of each contrast for each individual to obtain a mean regional beta value. This was taken as a measure of mean M1 activation during a particular motor task. We tested whether the contralesional M1 region shows higher

Notes to Table 2;

The table shows the location and extent of the infarct in each patient (11 right-hemisphere and 7 left-hemisphere lesion patients). Patient numbers correspond to that in Table 1. A composite image showing the overlap of lesions in all 18 patients (left hemisphere lesions were flipped along the mid-sagittal plane) is shown in the bottom right of the table. The horizontal color scale indicates the degree of overlap of lesions on a voxel-by-voxel basis (yellow and red colors indicate maximal overlap between lesions). Columns 3 and 6 indicate which of the motor areas among primary motor cortex (M1), dorsal premotor (PMd) and Supplementary Motor Area (SMA) are involved in each patient. For definition of the gross-anatomical delineations of M1, PMd and SMA, see Materials and methods. (For interpretation of the references to colour in this table legend, the reader is referred to the web version of this article.)

beta-values than the lesional M1 during movements of the recovered hand. Higher beta-values in the contralesional M1 (compared to the lesional M1) might be due to disinhibition of the contra-lesional hemisphere.

Translating disinhibition of the contralesional hemisphere into changes in TMS parameters investigated in this study (transcallosal inhibition, ICI and ICF), we expected:

- i) larger transcallosal inhibition from the contralesional to the lesional (CtoL) than from the lesional to the contralesional (LtoC) hemisphere; i.e., CtoL/LtoC > 1 (Murase et al., 2004)
- ii) greater intracortical inhibition (ICI) in the lesional than the contralesional hemisphere (Shimizu et al., 2002; Bütefisch et al., 2003) or
- iii) greater intracortical facilitation (ICF) in the contralesional than the lesional hemisphere.

Results

fMRI activation patterns

All patients and control subjects were able to perform the tasks at the required pace. Mirror movements or proximal synkinesias were not observed in any patient. Mean brain activation (task–rest) for each task was examined for all patients ($N=18$), for patients grouped by their infarcted hemisphere (right hemisphere lesion; $N=11$ and left hemisphere lesion patients; $N=7$) and for control subjects ($N=11$). In addition to activation in the contralateral sensorimotor cortex, bilateral cerebellum and SMA for all tasks, patients recruited ipsilateral sensorimotor cortex during the recovered hand tasks (both wrist and index finger) and contralateral premotor cortex for the recovered wrist task (all activations significant at FDR corrected $p < 0.05$). However, the recovered index finger movements showed this pattern of activation only at a lower statistical threshold ($p < 0.001$ uncorrected). Mean brain activation in control subjects ($p < 0.05$, FDR corrected) was similar to patients in that they recruited bilateral sensorimotor cortices, SMA and cerebellum during the left-hand tasks. However, bilateral cerebellar activation was seen only during the left-index finger task. Separating patients into right and left hemisphere-lesion groups did not yield significantly different patterns of activation

compared to when all patients were grouped together and contrasted to the control group.

A voxel by voxel comparison between groups (patients_($N=18$) > controls_($N=11$)) revealed that patients in general exhibited more brain activation than controls. This analysis was done after the brain images of seven patients with left hemisphere lesions were flipped to create a group of patients who had only right hemisphere lesions (Table 3; see details in the methods section and pros and cons in the discussion). Wrist movement of the recovered hand showed more bilateral sensorimotor cortex activation (Fig. 1a) while that of the non-affected hand resulted in a greater activation in the contralateral sensorimotor cortex (Fig. 1b) in patients compared to control subjects. For the index finger abduction–adduction movements (both recovered and non-affected hands), in addition to the contralateral sensorimotor cortex, patients exhibited more activation in the SMA and ipsilateral cerebellum than the control subjects (Fig. 2). Patients showed greater activation than control subjects during both the wrist and index finger tasks (see Table 3), with the affected hand tasks resulting in stronger activation (higher T-values) in the contralateral SM1 compared to the non-affected hand tasks. The reverse comparison (controls > patients) did not reveal significant difference ($p < 0.001$) in activation in any brain region for any task.

Expecting changes in the somatotopic organization of the primary motor cortex after recovery from stroke, we examined the location (x, y, z coordinates in the Talairach space) of the voxel with peak activation in the sensorimotor cortex across all tasks in both patient groups (right and left hemisphere lesions) and control subjects. Comparing the brain activity of the left hemisphere lesion group to control subjects during the right-index finger task (the recovered hand, in this group), we found that the voxel with peak activation (mean activation in the left hemisphere lesion group) was on average 7 mm ($p = 0.01$; $t = 2.64$) anterior to that in the control group. Patients with right hemisphere lesions showed a non-significant trend for a posterior shift (3 mm) in the location of peak activation compared to control subjects.

TMS

The resting motor threshold (RMT) in the lesional and contralesional hemispheres did not differ significantly in our group of patients (paired t -tests; $p < 0.36$). Averaged input–output data

Table 3
Details of brain activation

Task	# voxels in the cluster	x, y, z , coordinates (Talairach)	T value (voxel with peak activation)	Functional brain area
Non-affected wrist	55	–32 –26 54	4.16	Contralesional SM1
Affected wrist	140	36 –22 50	4.63	Lesional SM1
	32	–56 –20 38	4.18	Contralesional SM1
Non-affected index	35	–54 –18 44	4.58	Contralesional SM1
	65	14 –52 –16	4.63	Lesional Cer
	29	4 –4 56	4.13	SMA
Affected index	213	40 –20 50	6.85	Lesional SM1
	37	–14 –54 –20	4.57	Contralesional Cer
	44	4 2 54	3.93	SMA

The table shows brain areas that were significantly more active in patients ($N=18$) compared to control subjects (patients > controls) across all tasks. The brains of patients with left hemisphere lesions were flipped along the mid-sagittal plane so that all patients can be considered to have had right hemisphere lesions. All activations were significant at $p < 0.001$ and a cluster containing at least 20 voxels. SM1—primary sensorimotor cortex comprising M1 and S1; SMA—Supplementary Motor Area. Cer—cerebellum.

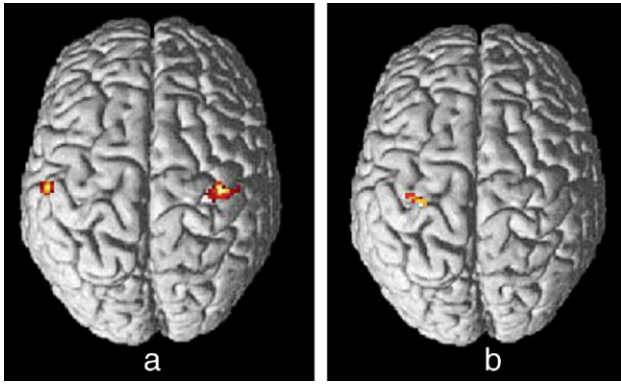


Fig. 1. Patients showed more activation ($p < 0.001$) than control subjects (patients–control subjects) in bilateral sensorimotor cortices during the recovered wrist movement (panel a, affected, left wrist movements) and only in the left sensorimotor cortex during the non-affected (right) wrist movement.

plotted using area under the MEPs evoked by increasing stimulus strengths, showed similar curves for both the infarcted and contralesional hemispheres. The mean ICI and ICF of patients are shown in Fig. 3. Neither ICI nor ICF was significantly different between the lesional and contralesional hemispheres in this group of patients. However, in five out of eight patients, ICI and ICF showed evidence consistent with disinhibition of the contralesional hemisphere; i.e., ICI in the lesional > contralesional and ICF in the contralesional > lesional (Table 4). This trend is evident in Fig. 3, which depicts mean ICI and ICF of all subjects.

The third TMS parameter of interest, transcallosal inhibition, was expressed as a percentage inhibition (test/control) of the MEP. This ratio during the contralesional to lesional (CtoL) and the reverse (LtoC) stimulation when examined, revealed that five out of eight subjects, showed a pattern consistent with disinhibition i.e., CtoL/LtoC > 1 (see Table 4). It may be noted that these patients have lesions mainly in the cortex/immediate underlying subcortical brain region and not in the deep white matter/striato-capsular region.

Table 4 shows how the mean regional beta values in the contralesional M1 are related to TMS parameters of disinhibition in eight patients in whom complete TMS data were available. Mean beta values during the affected index finger task were higher

in the contralesional M1 than in the lesional M1, in four out of eight patients (see beta values in Table 4) with complete TMS data.

To determine the functional role of the contralesional sensorimotor cortex (ipsilateral to the recovered hand) in recovery and to verify whether the descending uncrossed pyramidal fibers from the contralesional M1 to the recovered hand contribute directly to motor recovery, TMS was applied at the maximal stimulator output to the contralesional M1, while recording MEPs from both the recovered and non-affected FDI muscles. No MEPs were recorded in the recovered hand (ipsilateral to TMS stimulation) in any of the subjects studied.

Discussion

Patients had more bilateral sensorimotor cortical activation compared to control subjects during the recovered wrist task. The same pattern (i.e., SM1 activation higher in patients than controls) was seen for the recovered index finger task; however, patients showed additional activation of SMA and cerebellum during the recovered index finger task (compared to controls). The index finger abduction–adduction movements being more distal than the wrist, return later during the recovery process and require more fine control than the wrist flexion–extension movements (Brunnstrom, 1966; Fugl-Meyer et al., 1975; Duncan et al., 2000). Activation of secondary motor areas such as the SMA and the cerebellum during this task is most probably secondary to the neural demands of such fine control. In the absence of behavioral measures such as finger tapping speed or muscle force measurement, we cannot determine whether it is the increased neural demand for motor planning/preparation or increased muscle force that well-recovered stroke patients need to employ in order to perform motor tasks using the recovered hand. It is interesting to note that the greater contralateral sensorimotor cortex activation in patients during the wrist and index finger tasks when compared to control subjects was seen not just for the recovered hand tasks but for the non-affected hand tasks as well. Increased activation in the healthy hemisphere is most likely due to loss of inhibition that occurs from the lesional hemisphere to the healthy hemisphere (Liepert et al., 2000). Indeed, previous studies have established that, in normal subjects, inhibitory transcallosal conduction occurs between the contralateral and ipsilateral motor cortices during unimanual motor tasks (Allison et al., 2000; Kobayashi et al., 2003). One of the important observations from

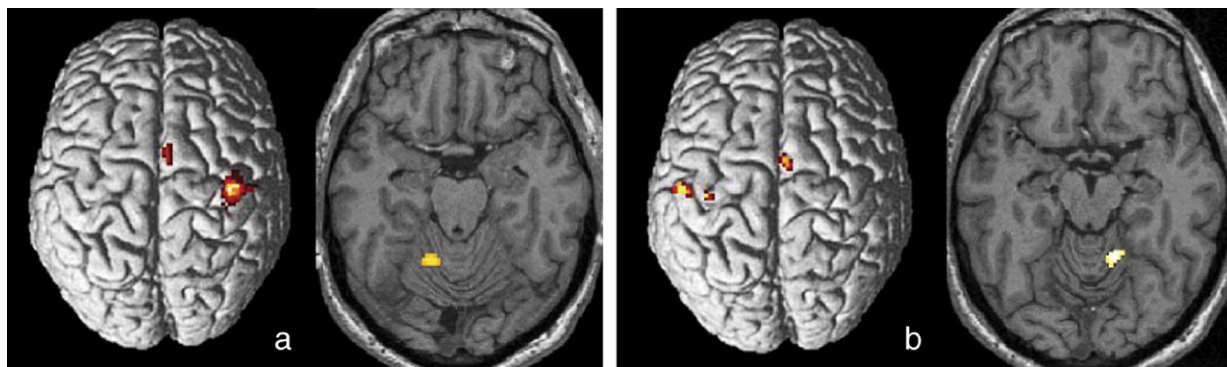


Fig. 2. During the index finger task, patients showed more activation ($p < 0.001$) than control subjects (patients–control subjects) in the SMA and ipsilateral cerebellum, in addition to the contralateral sensorimotor cortex, both for the recovered (panel a, left index finger movements) and non-affected hand (panel b, right index finger movements) tasks.

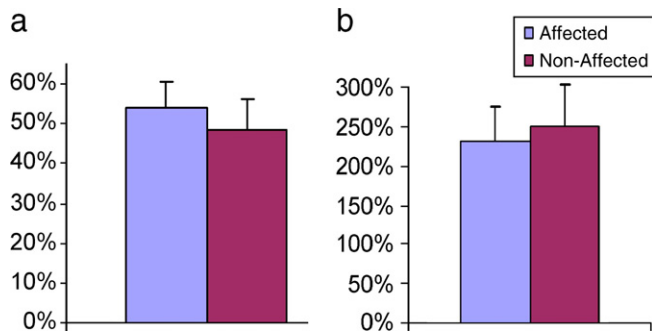


Fig. 3. Mean and standard error (SE) of intracortical inhibition (panel a; ICI) and intracortical facilitation (panel b; ICF) in patients. ICI is expressed as the percentage of the degree of inhibition ($1 - [\text{test}/\text{control}]$) and ICF is expressed as the percentage increase ($\text{test}/\text{control}$) in peak-to-peak MEP amplitude.

the above results is that the M1 of the lesional hemisphere is consistently activated in both the wrist and index finger tasks in well-recovered stroke patients. Hence activation in the lesional M1 might be a crucial aspect of good recovery (Cramer et al., 2002) and may even be a functional imaging marker of motor recovery. This finding agrees with several previous studies, which reported that with functional recovery, focusing of the initial over-activation seen in stroke patients mainly occurs to the ipsilesional M1 (Nelles et al., 1999; Marshall et al., 2000; Calautti et al., 2001; Cramer et al., 2002; Feydy et al., 2002; Ward et al., 2003; Binkofski and Seitz, 2004; Carey et al., 2005). Greater and widespread neural activation has been reported in previous studies of stroke recovery, both cross-sectional and longitudinal (Chollet et al., 1991; Weiller et al., 1992; Cramer et al., 1997; Cramer, 1999; Nelles et al., 1999; Marshall et al., 2000; Calautti et al., 2001; Ward et al., 2003; Carey et al., 2005). It seems that the system is somehow “upregulated” for execution of any movement and it is possible that such an increase in neural activity is essential to send sufficient signal to the motor neurons downstream. More activation in the sensorimotor cortex, SMA and cerebellum also reinforces the idea that increased reliance on brain structures involved in motor control may be an integral part of reorganization of motor systems (Bütefisch et al., 2005).

In this study, we flipped the brain of patients with left hemisphere infarcts to create a new, combined group of patients with only right hemisphere lesions (the true right hemisphere stroke patients and the

flipped, left hemisphere stroke patients). We are aware of the drawbacks of this approach, especially because the two hemispheres show some differences in their symmetry (Amunts et al., 2000). In addition, lesion location-specific mechanisms for neural reorganization have been shown to exist in chronic stroke patients (Luft et al., 2004a). However, this is frequently done (Nelles et al., 1999; Pineiro et al., 2001; Luft et al., 2004a,b; Ward et al., 2004) in order to create a group of patients large enough to provide statistically valid results and to draw conclusions relevant to the population.

When we analyzed data according to the hemisphere affected (thus separating the groups again into left and right hemisphere lesion groups), we observed a significant anterior shift in peak activation in M1 of the lesional hemisphere in left-hemisphere stroke patients during the affected index finger task. The right hemisphere group did not show any significant difference, although, the mean peak activation was 3 mm posterior compared to the control group. A change in the location of neural activation can be construed as evidence for an adaptive response resulting from the plasticity of the human cortex and is consistent with two theories of motor recovery following stroke, vicariance of function and demasking (Cramer, 1999; Jacobs and Donoghue, 1991). An anterior displacement of the center of gravity of motor maps during acute stroke recovery has been reported by a longitudinal TMS study (Delvaux et al., 2003). A posterior shift in SM1 coordinates was reported in a group of patients with subcortical stroke, using fMRI (Pineiro et al., 2001) and PET (Calautti et al., 2003). Evidence for the existence of a shift in motor maps in both, anterior and posterior directions in the cortex indicates that this process may depend on factors such as the location and extent of the lesion within the cortex, the varying range of time elapsed after the stroke in our group of patients and the type of rehabilitative therapy patients received.

The finding of similar resting motor thresholds (RMT) and input–output curves in the lesional and contralesional hemisphere in our patients suggests that neuronal excitability of corticospinal neurons in both the hemispheres is almost the same following good recovery. This by itself can be considered as a marker of motor recovery. However, we did find evidence for persistent changes in transcallosal inhibition in some of our well-recovered patients, in the form of a larger inhibition from the contralesional to the lesional hemisphere (Murase et al., 2004), than from the lesional to the contralesional hemisphere. This difference in transcallosal inhibition (Kobayashi et al., 2003, 2004) is probably the result of loss of inhibition (disinhibition) from the lesional hemisphere to

Table 4
Relation of fMRI and TMS parameters

Patient #	fMRI mean beta during the affected index finger task		Transcallosal: (CtoL/LtoC) > 1	ICI: lesional > contralesional hemisphere	ICF: contralesional > lesional hemisphere
	Contra-lesional M1 (C)	Lesional M1 (L)			
2	0.06	0.14	*	*	*
3	0.38	0.34	*		
4	0.07	0.17		*	*
8	0.91	0.62	*		
9	0.49	0.09		*	*
12	1.04	1.78		*	*
16	0.33	1.06	*	*	*
17	0.11	0.01	*		

The association of TMS parameters with fMRI beta values during the index finger task in eight patients (patient numbers correspond to numbers in Table 1). A * sign indicates that the parameter was identified in that patient. M1—primary motor cortex; CtoL—Contralesional to Lesional hemisphere; LtoC—Lesional to Contralesional hemisphere; ICI—intracortical inhibition; ICF—intracortical facilitation.

the contralesional hemisphere that remains even after the patient functionally recovers from stroke. The incidental observation that these patients who showed evidence of disinhibition mainly had infarcts in the cortex/immediate underlying subcortical brain region and not in the deep white matter/striato-capsular region, suggests that disinhibition may be a phenomenon more likely to persist in stroke patients with predominantly cortical lesions. We are aware that this proposition might be premature, considering that we could not find evidence for disinhibition consistently in all of our patients on whom we have TMS data. Data from a larger group of subjects are needed to verify this proposal. Nevertheless, it may well be that disinhibition of the contralesional hemisphere secondary to infarction and loss of cortical neurons is to a certain extent irreversible and that neural plasticity mechanisms evolve around this disinhibition, in order to optimize motor recovery. It must be mentioned, however, that evidence to contradict this proposition exists. Johansen-Berg et al. (2002a) observed the phenomenon of disinhibition during the early post-stroke period and suggested that as evidence for poor recovery. Some studies observed an improvement in motor function after inducing a “virtual lesion” in the contralesional M1 (and hence a decrease in disinhibition) of stroke patients using 1 Hz repetitive TMS (Mansur et al., 2005) and cathodal Transcranial Direct Current Stimulation (TDCS) (Fregni et al., 2005). Similar results were recently reported in healthy subjects by applying cathodal TDCS to the ipsilateral M1 (Vines et al., 2006). From these studies, it seems that inhibiting the contralesional M1 is one way to improve function of the lesional M1. Yet, we know from our results and others (Gerloff et al., 2006) that the uncrossed corticospinal tract from the contralesional M1 is not directly involved in the return of motor activity in the recovered hand, because MEPs were not recorded in the ipsilateral (recovered) FDI while stimulating the contralesional hemisphere using TMS, even at maximal stimulator output (Foltys et al., 2003) (despite contralesional M1 activation during wrist and index finger tasks in patients).

It must be remembered that failure to elicit ipsilateral MEPs does not by itself preclude a functional role for the contralesional M1 in recovery, since the contralesional M1 could potentially influence alpha motor neurons through polysynaptic connections. Thus, if activation in the contralesional M1 persists during the initial post-stroke period (Marshall et al., 2000; Calautti et al., 2001; Johansen-Berg et al., 2002a; Carey et al., 2002) and even after good recovery, and this area does not relay direct corticomotoneuronal connections, it is reasonable to conclude that contralesional M1 activation arises out of altered intracortical and transcallosal interactions. An alternative explanation is that contralesional M1 activation arises from top-down activation from higher order areas, and is an epiphenomenon not contributing to recovery. Gerloff et al. (2006) using EEG coherence analysis recently showed that after stroke, corticocortical connections were reduced in the stroke-affected hemisphere but increased in the contralesional hemisphere, suggesting a shift of functional connectivity towards the contralesional side. Short and long-range connectivity from within (Fridman et al., 2004) and across the hemisphere (Johansen-Berg et al., 2002b) is known to affect the excitability of the cortex and hence contribute to motor recovery. For instance, Johansen-Berg et al. (2002b) reported that by interrupting the contralesional dorsal premotor cortex using a TMS pulse 100 ms after the cue to move, patients, but not control subjects, showed a slowing of the index finger movement of the affected side. More and more evidence suggests that the recovery

process involves recruitment of brain areas functionally connected to the lesional M1 in both the hemispheres (Johansen-Berg et al., 2002a,b; Fridman et al., 2004; Gerloff et al., 2006).

In summary, return of neural activation in the lesional hemisphere, as evidenced by the fMRI BOLD signal increase in the lesional M1 and demonstrable MEPs in the recovered FDI using TMS on the lesional hemisphere, seems to be signatures of motor recovery following stroke. Second, compared to movements that recover earlier, movements that return later during the recovery process and those that involve fine motor control are represented by a larger network including the sensorimotor cortex, SMA and cerebellum. Third, functional imaging can identify markers of adaptive plasticity in the human brain such as a shift in location of peak activity. Such observations fit well with the current theories of motor recovery from stroke such as vicarious function. Fourth, the contralesional M1 does not affect recovery through the uncrossed corticospinal tract. Persistent contralesional M1 activation in patients well recovered by standardized criteria, might indicate altered intracortical and transcallosal interactions. Finally, TMS results suggest that residual disinhibition of the contralesional M1 may be observed even in well-recovered patients.

Acknowledgments

This research was supported by NIH grant RO1 #NS045049 to G.S. and K24 RR018875 to A.P.-L. We thank our patients for their commitment to the study and Astrid von Bueren Jarchow, Anders Green and Martin Kotynek-Friedl for their help with data collection.

References

- Allison, J.D., Meador, K.J., Loring, D.H., Figueroa, R.E., Wright, J.C., 2000. Functional MRI cerebral activation and deactivation during finger movement. *Neurology* 54, 135–142.
- Amunts, K., Jancke, L., Mohlberg, H., Steinmetz, H., Zilles, K., 2000. Interhemispheric asymmetry of the human motor cortex related to handedness and gender. *Neuropsychologia* 38, 304–312.
- Binkofski, F., Seitz, R.J., 2004. Modulation of the BOLD-response in early recovery from sensorimotor stroke. *Neurology* 63, 1223–1229.
- Brett, M., Leff, A.P., Rorden, G., Ashburner, J., 2001. Spatial normalization of brain images with focal lesions using cost function masking. *NeuroImage* 14, 486–500.
- Brunnstrom, S., 1966. Motor testing procedures in hemiplegia based on sequential recovery stages. *Phys. Ther.* 46, 357–375.
- Bütefisch, C.M., Netz, J., Wessling, M., Seitz, R.J., Hömberg, V., 2003. Remote changes in cortical excitability after stroke. *Brain* 126, 470–481.
- Bütefisch, C.M., Kleiser, R., Körber, B., Müller, K., Wittsack, H.-J., Hömberg, V., Seitz, R.J., 2005. Recruitment of contralesional motor cortex in stroke patients with recovery of hand function. *Neurology* 64, 1067–1069.
- Calautti, C., Leroy, F., Guincestre, J.Y., Baron, J.C., 2001. Dynamics of motor network over activation after striatocapsular stroke. A longitudinal PET study using a fixed-performance paradigm. *Stroke* 32, 2534–2542.
- Calautti, C., Leroy, F., Guincestre, J.Y., Baron, J.C., 2003. Displacement of primary sensorimotor cortex activation after subcortical stroke: a longitudinal PET study with clinical correlation. *NeuroImage* 19, 1650–1654.
- Carey, J.R., Kimberley, T.J., Lewis, S.M., Auerbach, E.J., Dorsey, L., Rundquist, P., Ugurbil, K., 2002. Analysis of fMRI and finger tracking training in subjects with chronic stroke. *Brain* 125, 773–788.
- Carey, L.M., Abbott, D.F., Egan, G.F., Bernhardt, J., Donnan, G.A., 2005. Motor impairment and recovery in the upper limb after stroke: behavioral and neuroanatomical correlates. *Stroke* 36, 625–629.

- Chollet, F., Wise, R.J.S., Brooks, D.J., Dolan, R.J., Frackowiak, R.S., 1991. The functional anatomy of motor recovery after stroke in humans: a study with positron emission tomography. *Ann. Neurol.* 29, 63–71.
- Classen, J., Liepert, J., Wise, S.P., Hallett, M., Cohen, L.G., 1998. Rapid plasticity of human cortical movement representation induced by practice. *J. Neurophysiol.* 79, 1117–1123.
- Cramer, S.C., 1999. Stroke recovery: lessons from functional MR imaging and other methods of human brain mapping. *Phys. Med. Rehabil. Clin. North Am.* 10, 875–886.
- Cramer, S.C., Nelles, G., Benson, R.R., Kaplan, J.D., Parker, R.A., Kwong, K.K., Kennedy, D.N., Finklestein, S.P., Rosen, B.R., 1997. A functional MRI study of subjects recovered from hemiparetic stroke. *Stroke* 28, 2518–2527.
- Cramer, S.C., Mark, A., Barquist, K., Nhan, H., Stegbauer, K.C., Price, R., Bell, K., Odderson, I.R., Esselman, P., Maravilla, K.R., 2002. Motor cortex activation is preserved in patients with chronic hemiplegic stroke. *Ann. Neurol.* 52, 607–616.
- Delvaux, V., Alagona, G., Gerard, P., De Pasqua, V., Pennisi, G., de Noordhout, A.M., 2003. Post-stroke reorganization of hand motor area: a 1-year prospective follow-up with focal transcranial magnetic stimulation. *Clin. Neurophysiol.* 114, 1217–1225.
- Duncan, P.W., Min Lai, S., Keighley, J., 2000. Defining post-stroke recovery: implications for design and interpretation of drug trials. *Neuropharmacology* 39, 835–841.
- Duque, J., Hummel, F., Celnik, P., Murase, N., Mazzocchio, R., Cohen, L.G., 2005. Transcallosal inhibition in chronic subcortical stroke. *NeuroImage* 28, 940–946.
- Eickhoff, S.B., Stephan, K.E., Mohlberg, H., Grefkes, C., Fink, G.R., Amunts, K., Zilles, K., 2005. A new SPM toolbox for combining probabilistic cytoarchitectonic maps and functional imaging data. *NeuroImage* 25, 1325–1335.
- Feydy, A., Carlier, R., Roby-Brami, A., Bussel, B., Cazalis, F., Pierot, L., Burnod, Y., Maier, M.A., 2002. Longitudinal study of motor recovery after stroke: recruitment and focusing of brain activation. *Stroke* 33, 1610–1617.
- Foltys, H., Krings, T., Meister, I.G., Sparing, R., Boroojerdi, B., Thron, A., Topper, R., 2003. Motor representation in patients rapidly recovering after stroke: a functional magnetic resonance imaging and transcranial magnetic stimulation study. *Clin. Neurophysiol.* 114, 2404–2415.
- Fregni, F., Boggio, P.S., Mansur, C.G., Wagner, T., Ferreira, M.J., Lima, M.C., Rigonatti, S.P., Marcolin, M.A., Freedman, S.D., Nitsche, M.A., Pascual-Leone, A., 2005. Transcranial direct current stimulation of the unaffected hemisphere in stroke patients. *NeuroReport* 16, 1551–1555.
- Fridman, E.A., Hanakawa, T., Chung, M., Hummel, F., Leiguarda, R.C., Cohen, L.G., 2004. Reorganization of the human ipsilesional premotor cortex after stroke. *Brain* 127, 747–758.
- Friston, K.J., Ashburner, J., Frith, C.D., Poline, J.B., Heather, J.D., Frackowiak, R.S.J., 1995a. Spatial registration and normalization of images. *Hum. Brain Mapp.* 2, 165–189.
- Friston, K.J., Holmes, A.P., Worsley, K.J., Poline, J.B., Frith, C., Frackowiak, R.S.J., 1995b. Statistical parametric maps in functional imaging: a general linear approach. *Hum. Brain Mapp.* 2, 189–210.
- Fugl-Meyer, A.R., Jaasko, L., Leyman, I., Olsson, S., Steglind, S., 1975. The post-stroke hemiplegic patient I. A method for evaluation of physical performance. *Scand. J. Rehabil. Med.* 7, 13–31.
- Gerloff, C., Bushara, K., Sailer, A., Wassermann, E.M., Chen, R., Matsuoka, T., Waldvogel, D., Wittenberg, G.F., Ishii, K., Cohen, L.G., Hallett, M., 2006. Multimodal imaging of brain reorganization in motor areas of the contralesional hemisphere of well recovered patients after capsular stroke. *Brain* 129, 791–808.
- Jacobs, K.M., Donoghue, J.P., 1991. Reshaping the cortical motor map by unmasking latent intracortical connections. *Science* 251, 944–947.
- Johansen-Berg, H., Dawes, H., Guy, C., Smith, S.M., Wade, D.T., Matthews, P.M., 2002a. Correlation between motor improvements and altered fMRI activity after rehabilitative therapy. *Brain* 125, 2731–2742.
- Johansen-Berg, H., Rushworth, M.F., Bogdanovic, M.D., Kischka, U., Wimalaratna, S., Matthews, P.M., 2002b. The role of ipsilateral premotor cortex in hand movement after stroke. *Proc. Natl. Acad. Sci. U. S. A.* 99, 14518–14523.
- Kalra, L., Crome, P., 1993. The role of prognostic scores in targeting stroke rehabilitation in the elderly. *J. Am. Geriatr. Soc.* 41, 396–400.
- Karnath, H.O., Fruhmann-Berger, M., Kuker, W., Rorden, C., 2004. The anatomy of spatial neglect based on voxelwise statistical analysis: a study of 140 patients. *Cereb. Cortex* 14, 1164–1172.
- Kobayashi, M., Pascual-Leone, A., 2003. Transcranial magnetic stimulation in neurology. *Lancet Neurol.* 3, 145–156.
- Kobayashi, M., Hutchinson, S., Schlaug, G., Pascual-Leone, A., 2003. Ipsilateral motor cortex activation on functional magnetic resonance imaging during unilateral hand movements is related to interhemispheric interactions. *NeuroImage* 20, 2259–2270.
- Kobayashi, M., Hutchinson, S., Theoret, H., Schlaug, G., Pascual-Leone, A., 2004. Repetitive TMS of the motor cortex improves ipsilateral sequential simple finger movements. *Neurology* 62, 91–98.
- Kujirai, T., Caramia, M.D., Rothwell, J.C., Day, B.L., Thompson, P.D., Ferbert, A., Wroe, S., Asselman, P., Marsden, C.D., 1993. Corticocortical inhibition in human motor cortex. *J. Physiol.* 471, 501–519.
- Liepert, J., Hamzei, F., Weiller, C., 2000. Motor cortex disinhibition of the unaffected hemisphere after acute stroke. *Muscle Nerve* 23, 1761–1763.
- Luft, A.R., Waller, S., Forrester, L., Smith, G.V., Whittall, J., Macko, R.F., Schulz, J.B., Hanley, D.F., 2004a. Lesion location alters brain activation in chronically impaired stroke survivors. *NeuroImage* 21, 924–935.
- Luft, A.R., McCombe-Waller, S., Whittall, J., Forrester, L.W., Macko, R., Sorkin, J.D., Schulz, J.B., Goldberg, A.P., Hanley, D.F., 2004b. Repetitive bilateral arm training and motor cortex activation in chronic stroke: a randomized controlled trial. *JAMA* 292, 1853–1861.
- Mansur, C.G., Fregni, F., Boggio, P.S., Riberto, M., Gallucci-Neto, J., Santos, C.M., Wagner, T., Rigonatti, S.P., Marcolin, M.A., Pascual-Leone, A., 2005. A sham stimulation-controlled trial of rTMS of the unaffected hemisphere in stroke patients. *Neurology* 64, 1802–1804.
- Marshall, R.S., Perera, G.M., Lazar, R.M., Krakauer, J.W., Constantine, R.C., DeLaPaz, R.L., 2000. Evolution of cortical activation during recovery from corticospinal tract infarction. *Stroke* 31, 656–661.
- Meyer, B.U., Rörich, S., Graf von Einsiedel, H., Kruggel, F., Weindl, A., 1995. Inhibitory and excitatory interhemispheric transfers between motor cortical areas in normal humans and patients with abnormalities of the corpus callosum. *Brain* 118, 429–440.
- Mottaghy, F.M., Gangitano, M., Horkan, C., Chen, Y., Pascual-Leone, A., Schlaug, G., 2003. Repetitive TMS temporarily alters brain diffusion. *Neurology* 60, 1539–1541.
- Murase, N., Duque, J., Mazzocchio, R., Cohen, L.G., 2004. Influence of interhemispheric interactions on motor function in chronic stroke. *Ann. Neurol.* 55, 400–409.
- Nelles, G., Spiekermann, G., Jueptner, M., Leonhardt, G., Müller, S., Gerhard, H., Diener, H.C., 1999. Evolution of functional reorganization in hemiplegic stroke: a serial positron emission tomographic activation study. *Ann. Neurol.* 46, 901–909.
- Nudo, R.J., 2003. Functional and structural plasticity in motor cortex: implications for stroke recovery. *Phys. Med. Rehabil. Clin. North Am.* 14, S57–S76.
- Nudo, R.J., Plautz, E.J., Frost, S.B., 2001. Role of adaptive plasticity in recovery of function after damage to motor cortex. *Muscle Nerve* 24, 1000–1019.
- Pineiro, R., Pendlebury, S., Johansen-Berg, H., Matthews, P.M., 2001. Functional MRI detects posterior shifts in primary sensorimotor cortex activation after stroke. Evidence for local adaptive reorganization. *Stroke* 32, 1134–1139.
- Rorden, C., Brett, M., 2000. Stereotaxic display of brain lesions. *Behav. Neurol.* 12, 191–200.
- Rorden, C., Karnath, H.O., 2004. Using human brain lesions to infer function: a relic from a past era in the fMRI age? *Nat. Rev., Neurosci.* 5, 813–819.

- Rossini, P.M., Barker, A.T., Berardelli, A., 1994. Non-invasive electrical and magnetic stimulation of the brain spinal cord and roots: basic principles and procedures for routine clinical application: report of an ICFN committee. *Electroencephalogr. Clin. Neurophysiol.* 91, 79–91.
- Seitz, R.J., Roland, E., Bohm, C., Greitz, T., Stone-Elander, S., 1990. Motor learning in man: a positron emission tomographic study. *NeuroReport* 1, 57–60.
- Shimizu, T., Hosaki, A., Hino, T., Sato, M., Komori, T., Hirai, S., Rossini, P.M., 2002. Motor cortical disinhibition in the unaffected hemisphere after unilateral cortical stroke. *Brain* 125, 1896–1907.
- Theoret, H., Halligan, E., Kobayashi, M., Fregni, F., Tager-Flusberg, H., Pascual-Leone, A., 2005. Impaired motor facilitation during action observation in individuals with autism spectrum disorder. *Curr. Biol.* 15, R84–R85.
- Vines, B.V., Nair, D.G., Schlaug, G., 2006. Contralateral and ipsilateral motor effects after transcranial direct current stimulation. *NeuroReport* 17, 671–674.
- Ward, N.S., Brown, M.M., Thompson, A.J., Frackowiak, R.S., 2003. Neural correlates of motor recovery after stroke: a longitudinal fMRI study. *Brain* 126, 2476–2496.
- Ward, N.S., Brown, M.M., Thompson, A.J., Frackowiak, R.S., 2004. The influence of time after stroke on brain activations during a motor task. *Ann. Neurol.* 55, 829–834.
- Weiller, C., Chollet, F., Friston, K.J., Wise, R.J., Frackowiak, R.S., 1992. Functional reorganization of the brain in recovery from striatocapsular infarction in man. *Ann. Neurol.* 31, 463–472.
- Zilles, K., Schlaug, G., Matelli, M., Luppino, G., Schleicher, A., Qü, M., Dabringhaus, A., Seitz, R., Roland, P.E., 1995. Mapping of human and macaque sensorimotor areas by integrating architectonic, transmitter receptor, MRI, and PET data. *J. Anat.* 187, 515–537.